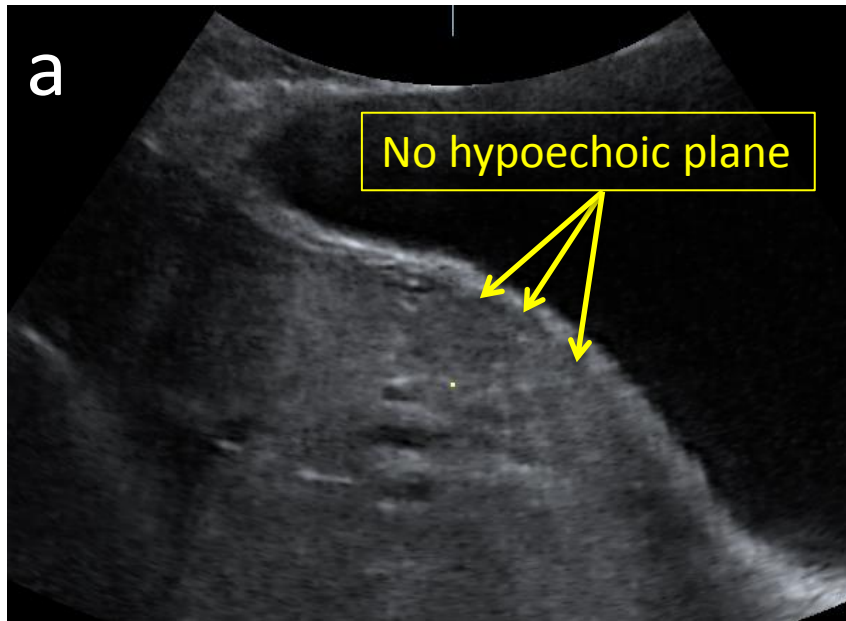


Collins *et al.*
EW-AIP descriptors

Sample images: abnormal and
normal and findings according to the
proposed descriptors

Figure S1 Loss of the 'clear zone'

- Abnormal



- Normal

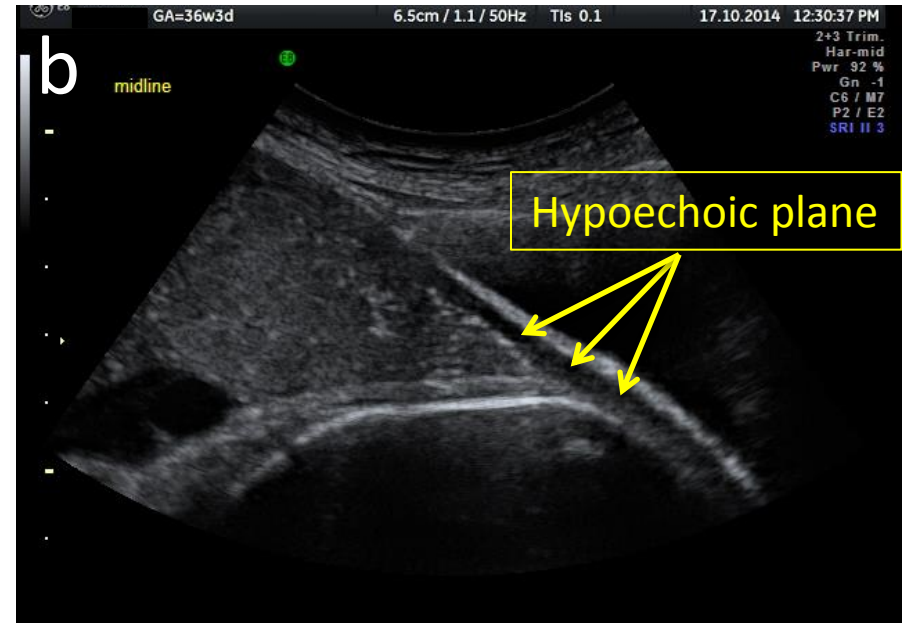
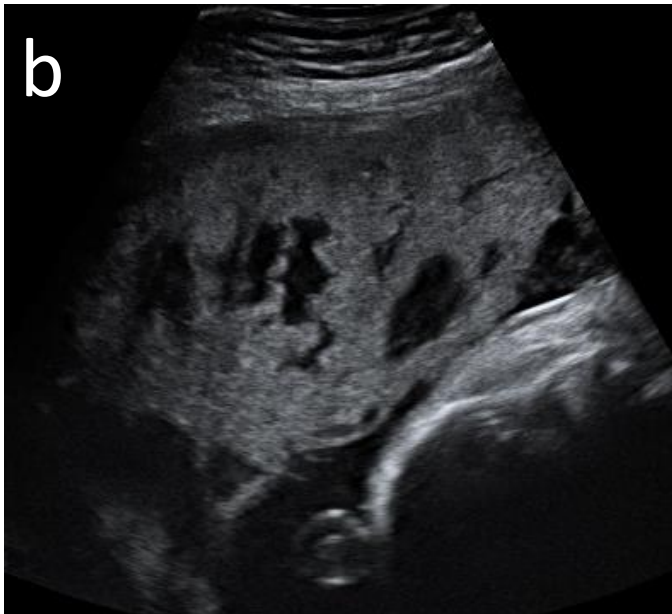
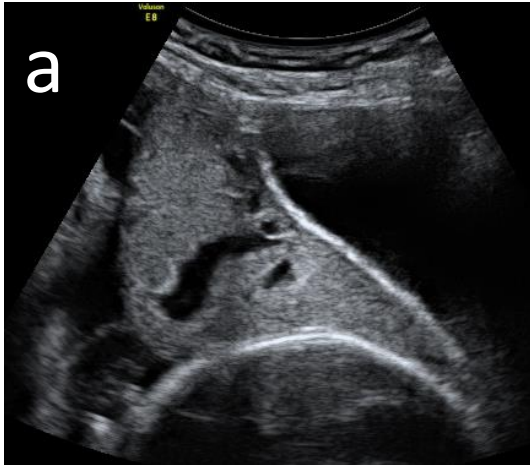
Figure S2 Abnormal placental lacunae

- Abnormal



- Normal

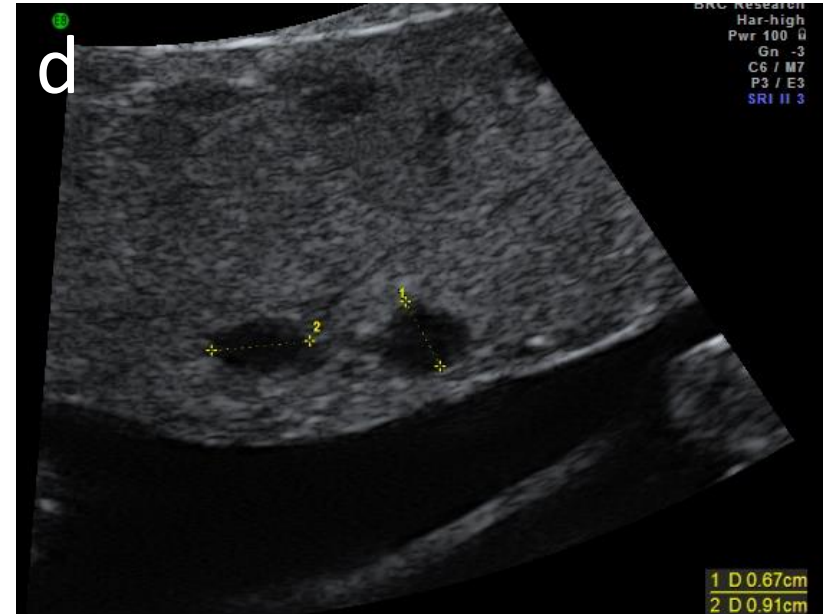
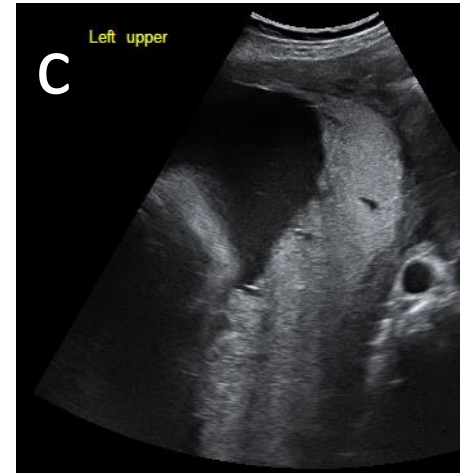
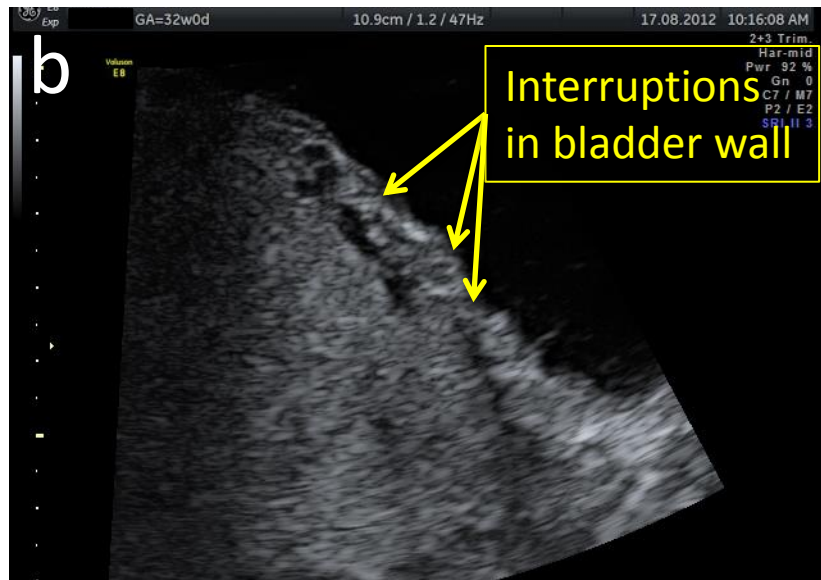
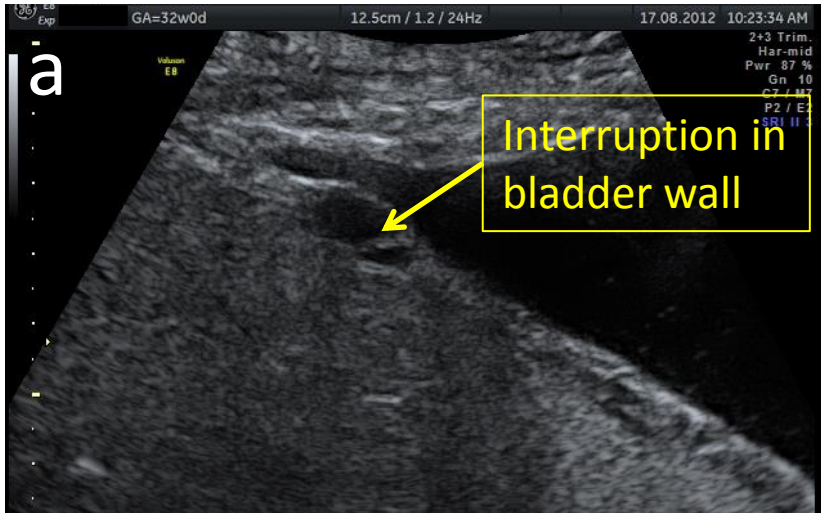


Figure S3 Bladder wall interruption

- Abnormal



- Normal

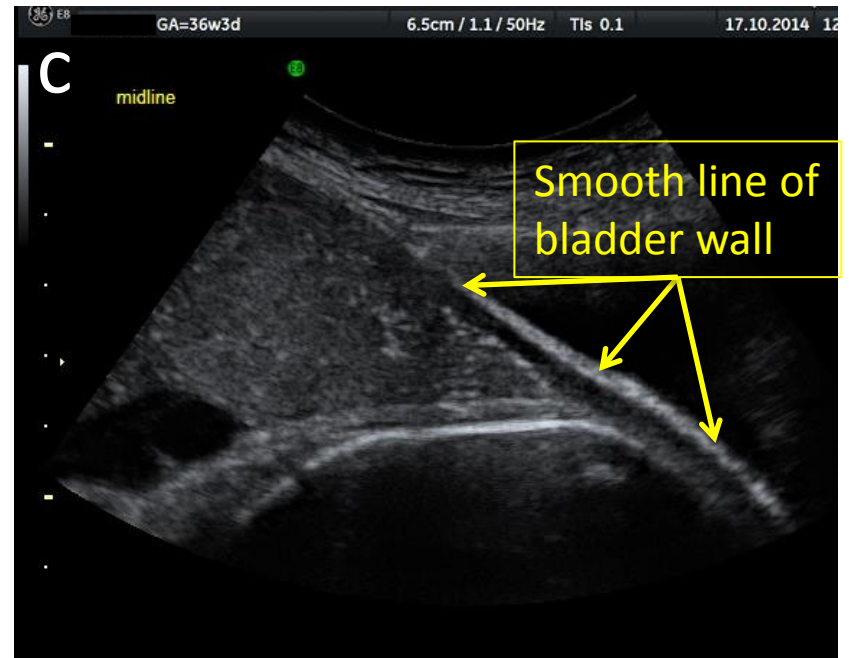
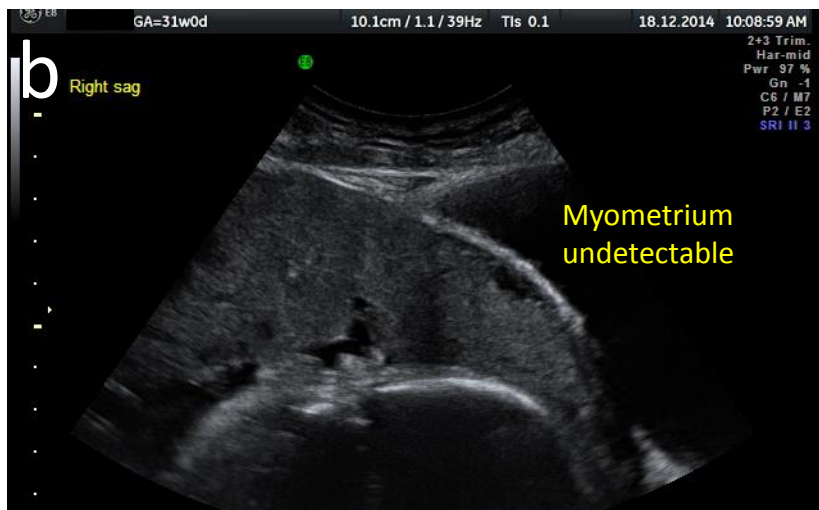
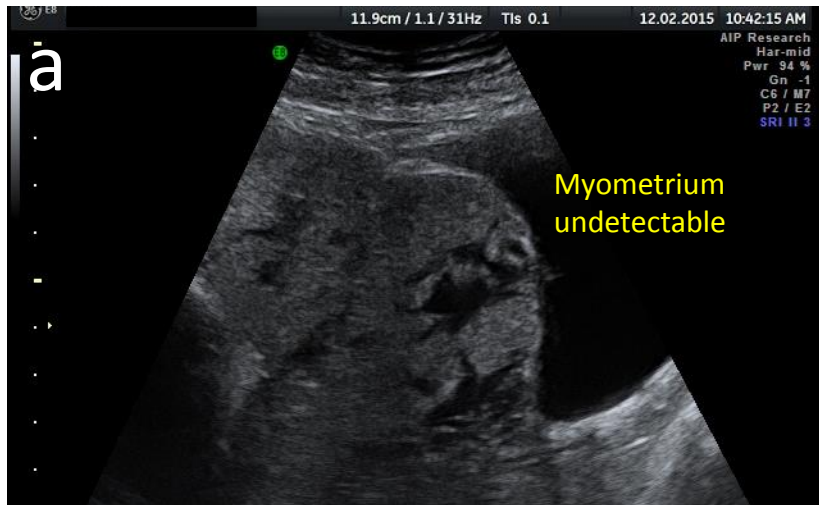


Figure S4 Myometrial thinning

- Abnormal



- Normal

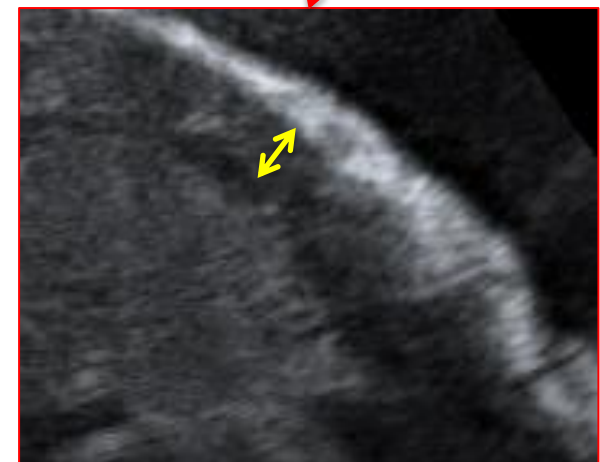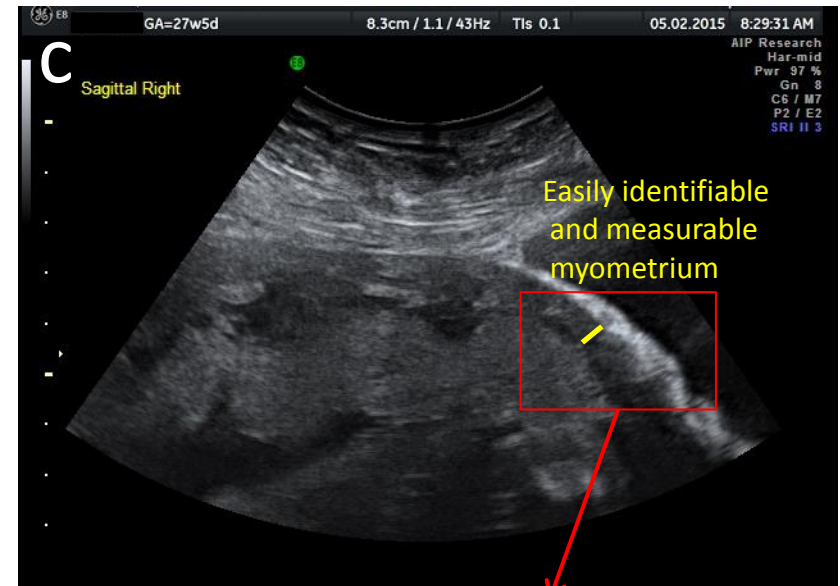
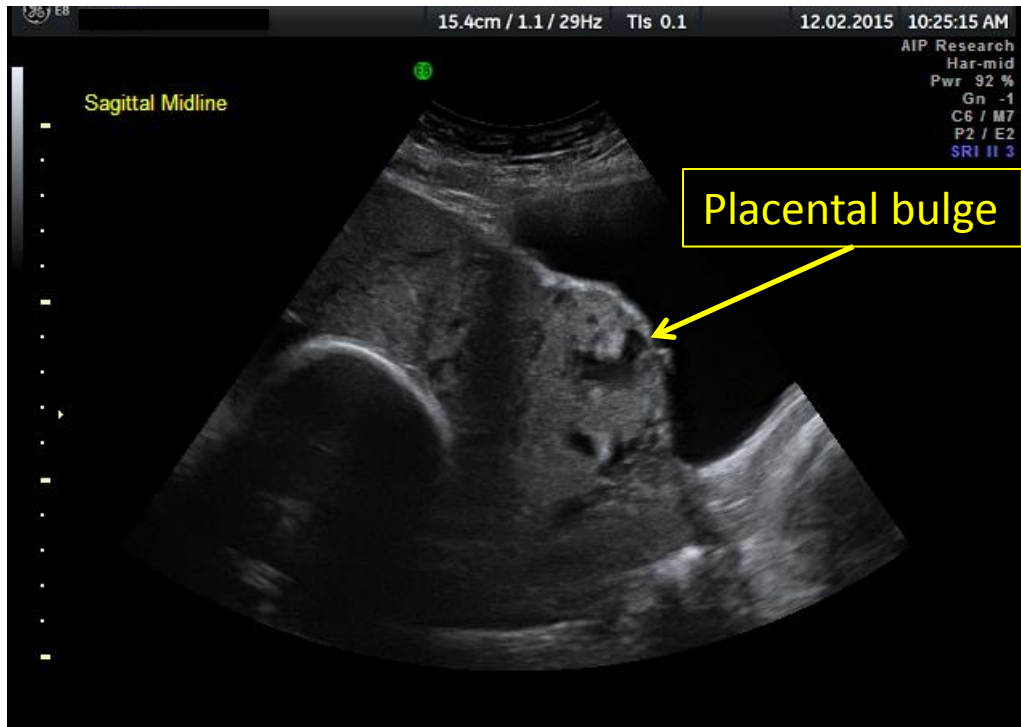


Figure S5 Placental bulge

- Abnormal

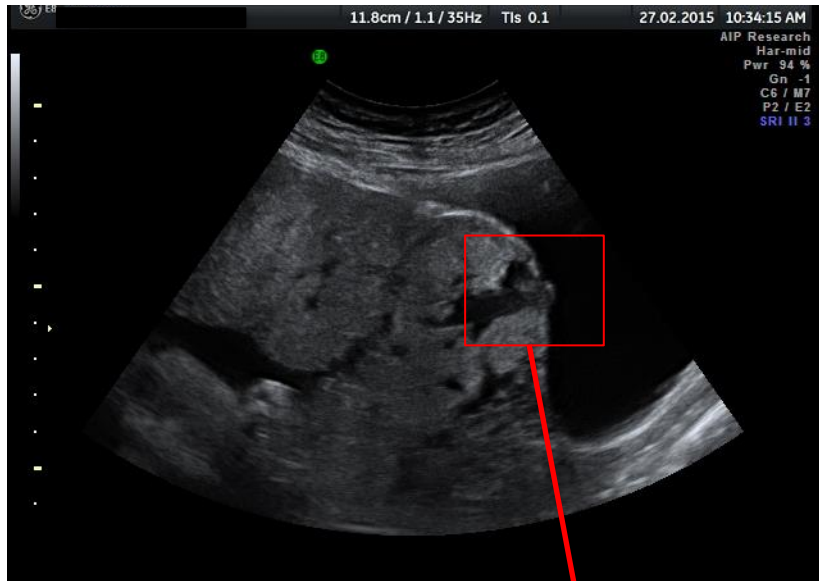


- Normal

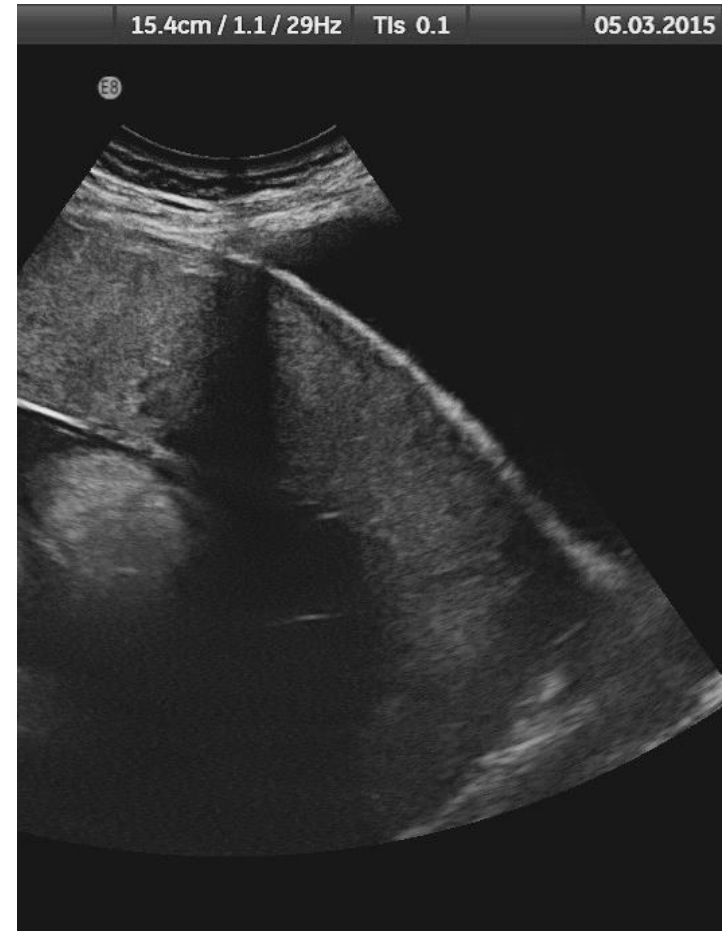
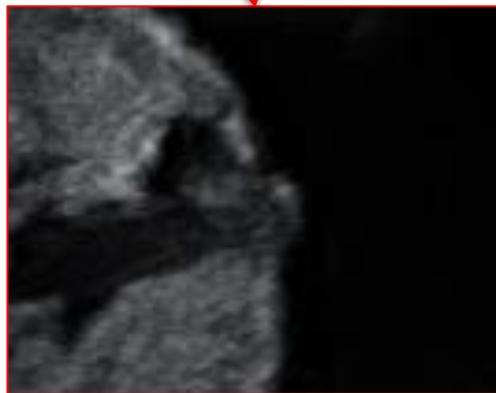
Figure S6 Focal exophytic mass

- Abnormal



- Normal

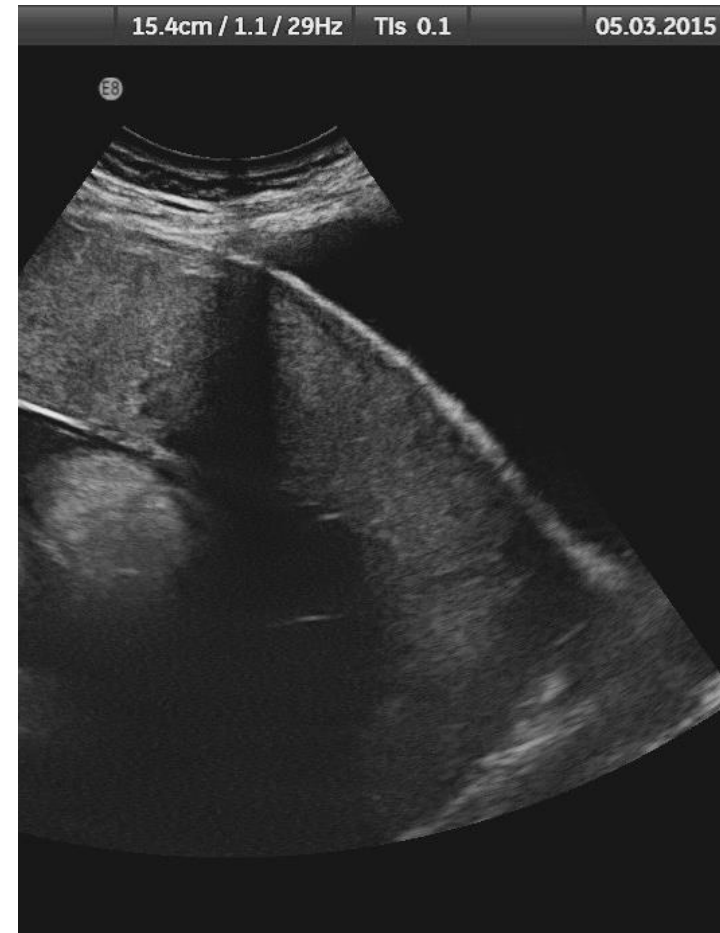
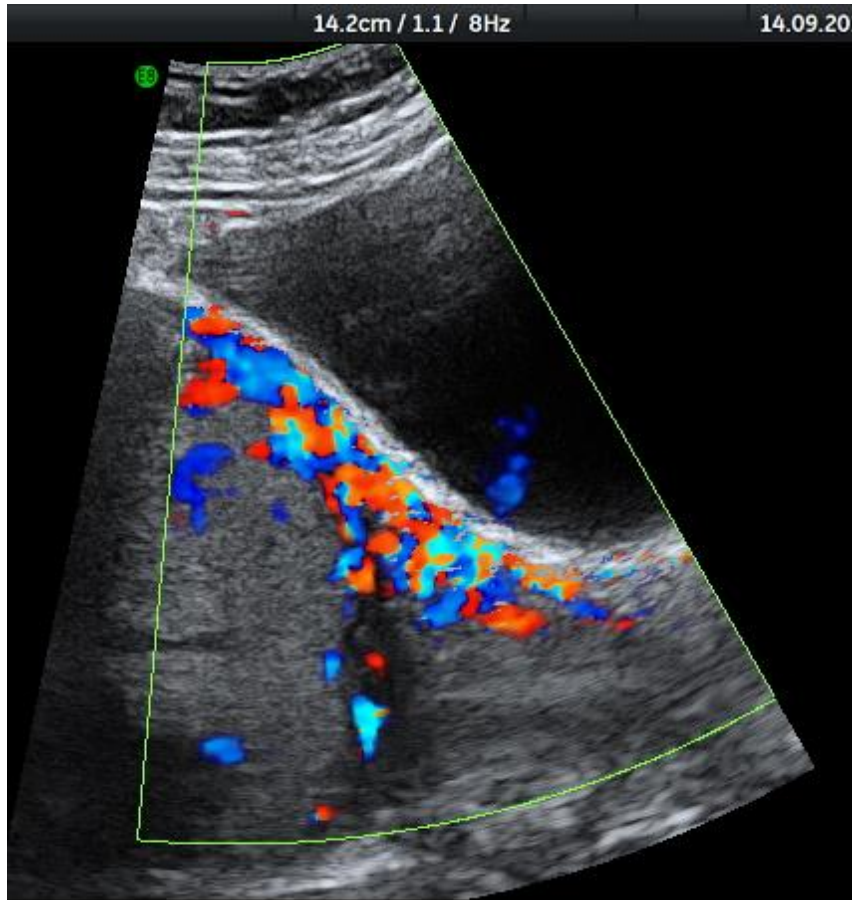


Figure S7 Uterovesical hypervascularity

- Abnormal



- Normal

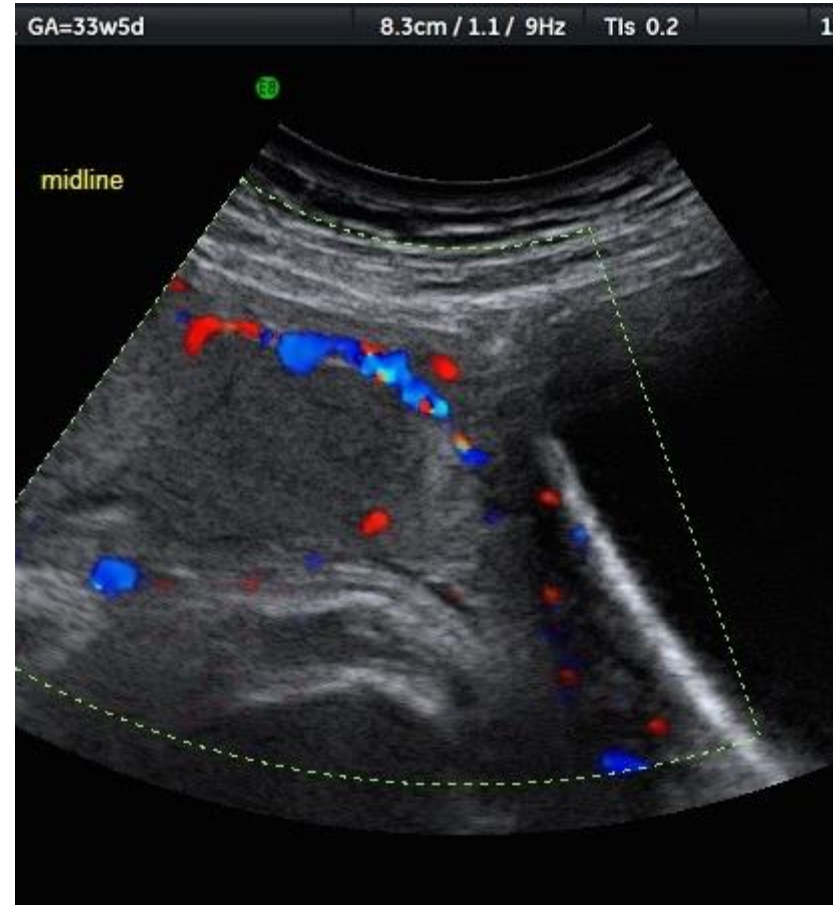
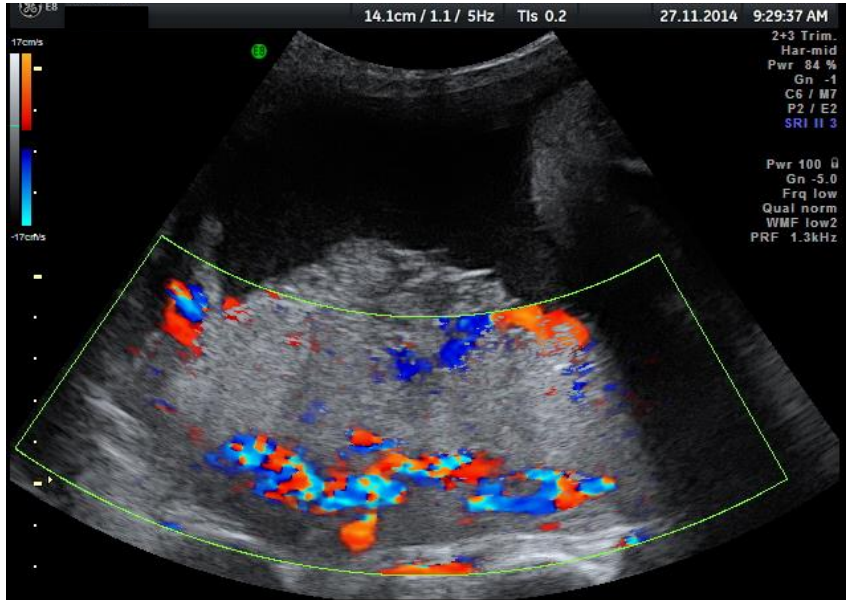


Figure S8 Subplacental hypervascularity

- Abnormal



- Normal

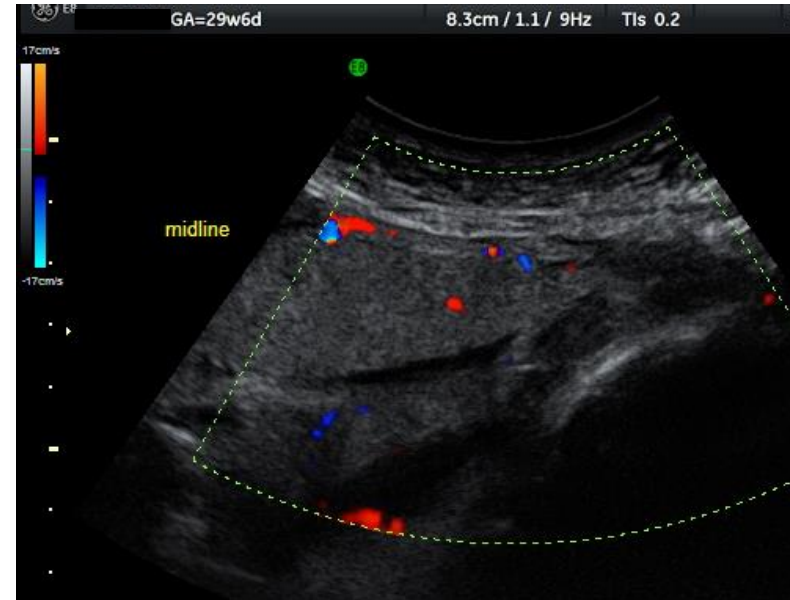


Figure S9 Bridging vessels

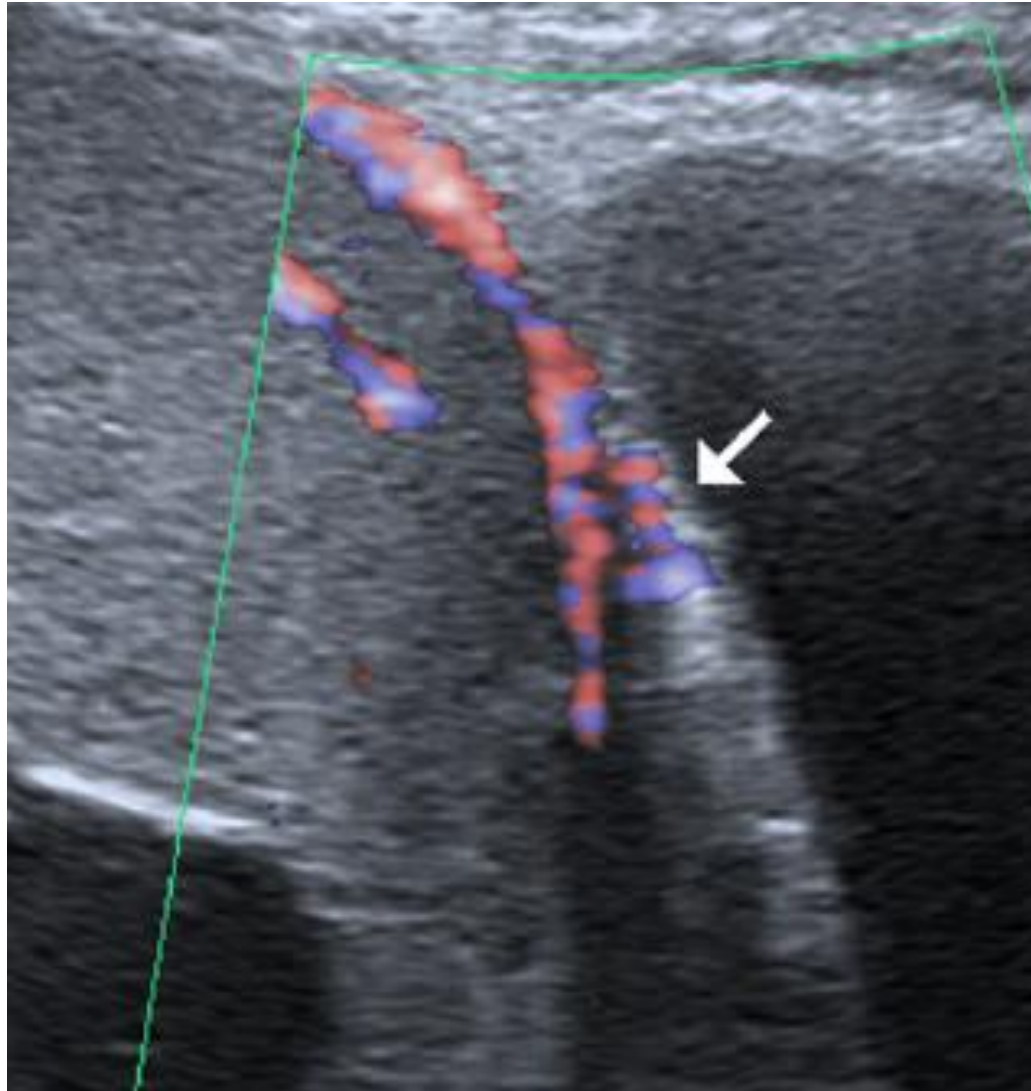


Figure S10 Placental lacunae feeder vessels

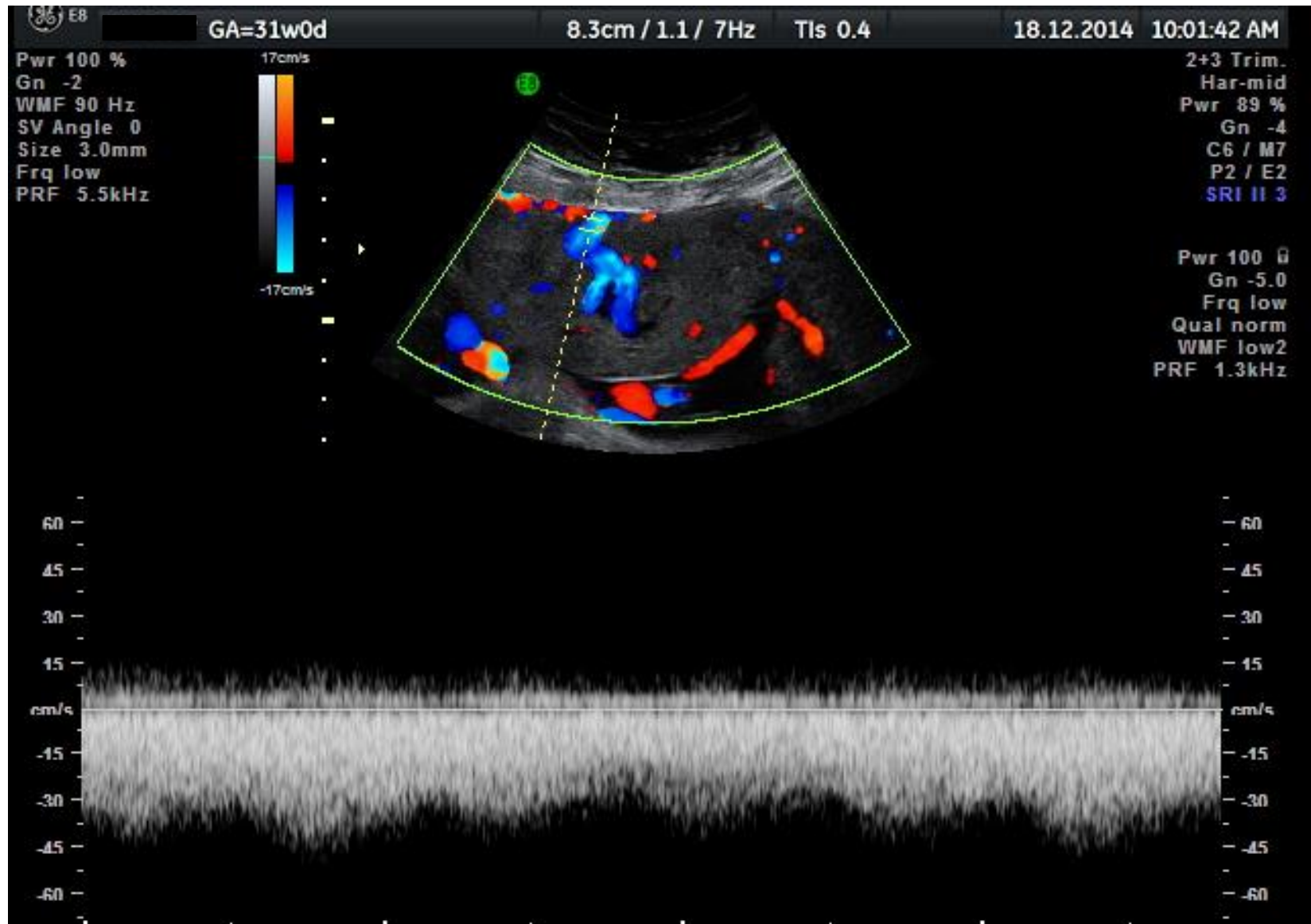


Figure S11 Intraplacental hypervascularity (3D power Doppler)

- Reproduced with permission from Shih *et al.*, *Ultrasound Obstet Gynecol* 2009; **33**: 193–203.

