Norske abstracts på Euroecho 2009

European Journal of Echocardiography, Volume 10 Supplement 2

M151. Quantitative contrast stress echocardiography in assessment of restenosis after percutaneous coronary intervention

MT Lonnebakken[1], EM Staal[2], Ö Bleie[3], OK Nygaard[1], E Strand[2], E Gerdts[1]. [1]Haukeland University Hospital and University of Bergen, Bergen, Norway; [2]University of Bergen, Bergen, Norway; [3]Haukeland University Hospital, Bergen, Norway

Background: Quantitative contrast stress echocardiography (CSE) can assess regional myocardial perfusion. The aim of this study was to evaluate the performance of quantitative CSE in detection of restenosis after percutaneous coronary intervention (PCI).

Methods: In 33 patients scheduled for PCI due to stable coronary artery disease, quantitative coronary angiography (QCA) and CSE were performed before and 9 months after PCI. Perfusion in each of the typical distribution areas of the coronary arteries was assessed by contrast replenishment curves, expressing total blood volume (A), blood flow velocity (β, perfusion rate (A×β, and refilling time (rt). Change in perfusion during stress was calculated before and after PCI and regions with angiographic restenosis (diameter stenosis ≥50%) were compared to successfully revascularised regions.

Results: A total of 38 significant coronary artery stenoses were eligible for PCI. At 9 months follow-up QCA detected 29 successful PCI and 9 restenosis. There was a significant increase in stress-induced perfusion in regions after successful PCI, but no significant change in stress-induced perfusion in regions supplied by restenotic arteries (Table). However, at 9 months follow-up, perfusion increase during peak stress did not differ significantly between groups of patients with successful PCI and restenosis (p=ns).

Conclusion: In patients who undergo pre- and post-interventional quantitative CSE, restenosis may be detected by lack of improvement in stress-induced perfusion after PCI.

Table 1 Stress-induced perfusion changes

	Sucessfull PCI (n=29)		Restenosis (n=9)	
	Before PCI	9 months after PCI	Before PCI	9 months after PCI
ΔA (%)	5.9 (1.6–12.2)	5.5 (−1.7–14.3)	10.0 (1.5–17.8)	9.7 (2.7–11.8)
Δβ (1/s)	−3.8 (−9.5–(−0.4))	0.1 (−2.7–3.6)*	2.0 (−3.1–3.6)	0.9 (−1.5–5.3)
ΔAxβ (1/s)	−175 (−561–(−15))	31 (−133–232)*	141 (−165–479)	66 (−41–413)
Δrt (ms)	259 (−24–493)	−99 (−247–125)*	8 (−91–253)	−79 (−268–163)

*Change in perfusion parameters during stress (median[25–75 percentile]),before and 9 months after PCI in sucessfully revascularized and restenotic regions. *p<0.05 within groups.*

M155. Perflutren protein-type a microspheres injectable suspension, USP do not increase mortality in critically ill patients: results from a retrospective propensity-matched case-control study.

JH Goldman[1], ML Main[2], A Exuzides[3], C Colby[3], S Feinstein[4], A Waaler[5], P Grayburn[6]. [1]ICON Medical Imaging, Warrington, United States of America; [2]St. Lukes' Mid America Heart Institute, Kansas City, United States of America; [3]ICON Clinical Research, San Francisco, United States of America; [4]Rush Presbyterian Medical Center, Chicago, United States of America; [5]GE Healthcare, Horten, Norway; [6]Baylor University Medical Center, Dallas, United States of America

Purpose: Due to serious cardiopulmonary reactions reported immediately following administration of perflutren containing contrast agents, the United States Food and Drug Administration (FDA) required a Black Box Safety warning for this class of agents including Perflutren Protein-Type A Microspheres Injectable Suspension, USP. The FDA has requested a database analysis to compare in-hospital mortality in critically ill patients undergoing echocardiography with and without

this contrast agent. This study provides results of the retrospective analysis.

Methods: The study utilized the largest available hospital service-level database in the U.S. Patients were characterized by diagnoses, dates of treatments, and outcomes. All adult patients undergoing inpatient echocardiography between Jan. 2003 and Oct. 2005 were identified (n=2,588,722 of which 22,499 received Perflutren Protein-Type A Microspheres Injectable Suspension, USP). Patients receiving other contrast agents were excluded from the study. From the 22,499 contrast echocardiography patients, 2,900 had diagnoses meeting defined criteria for critical illness (heart failure, acute myocardial infarction, arrhythmia, respiratory failure, pulmonary embolism, emphysema, and pulmonary hypertension). To control for the differences between the contrast and non-contrast patients we used propensity-score matching. Variables used in the construction of the propensity score included comorbidities, demographic factors, hospital-specific factors, level of care (e.g., intensive care unit or cardiac care unit), and mechanical ventilation status. Patients receiving contrast echocardiography were matched to 4 controls who received non-contrast echocardiography. Conditional logistic regression was used to estimate mortality effects.

Results: There were 167 deaths in the study among critically ill patients, 38/2900 from the contrast group and 129/11600 from the control group. The contrast agent was not associated with an increase in same-day mortality (odds ratio = 1.18 (95% C.I. 0.82, 1.71); P= 0.37)). Prior to matching, contrast patients showed greater morbidity then non-contrast patients (Deyo-Charlson Comorbidity Score 2.45 vs. 2.25, P<0.0001). After propensity-score matching these differences were significantly reduced, showing that both groups were well-balanced.

Conclusions : There is no increase in mortality in critically ill patients undergoing echocardiography with the contrast agent compared to case-matched controls.

P206. Assessment of myocardial strain may disclose right ventricular dysfunction in patients with intestinal carcinoid disease

LG Sahakyan[1], KH Haugaa[2], DS Bergestuen[3], E Thiis-Evensen[3], T Edvardsen[2]. [1]Yerevan State Medical University, Armenia/ Dept. of Cardiology, Rikshospitalet University Hospital, Oslo, Norway; [2]Dept. of Cardiology, Rikshospitalet University Hospital and University of Oslo, Oslo, Norway; [3]Dept. of Medicine, Rikshospitalet University Hospital, Oslo, Norway

Purpose: Cardiac fibrosis is an important complication of carcinoid disease leading typically to right-sided valvular dysfunction and heart failure. Current echocardiographic evaluation of right ventricular (RV) function in patients with carcinoid heart disease (CaHD) is limited and may be difficult due to its poorly defined geometry. CaHD is defined as the presence of at least mild right-sided valvular regurgitation or stenosis most often in the form of tricuspid regurgitation (TR). We hypothesized that assessment of myocardial strain by echocardiography may be useful for evaluation of early RV dysfunction in patients with CaHD.

Methods: We studied 89 patients with carcinoids (mean age 61±12; 47 females) and 20 healthy individuals (mean age 55±15; 7 females). Peak systolic strains were averaged from 3 myocardial segments in the RV free wall. We compared RV free wall strains in the patient group to the corresponding strains in the control group. Patients were divided into two groups according to the presence or absence of TR.

Results: Average RV strain was reduced in the patient group compared to the control group (20.6±5.0% vs 28.6±5.3%,p<0.001). Of the patients, 38 had mild or greater TR. There was no difference in RV function between the patients with and without TR (−21.2±4.5% vs −19.9±5.4%,ns), indicating early subclinical RV dysfunction even in carcinoid patients currently not fulfilling the criteria for CaHD.

Conclusions: RV function assessed by myocardial strain was lower in patients with intestinal carcinoid disease irrespective of valvular involvement compared to controls. These findings may indicate early RV involvement even in patients without right-sided valvular dysfunction. Myocardial strain may therefore disclose RV dysfunction in patients with intestinal carcinoid disease.

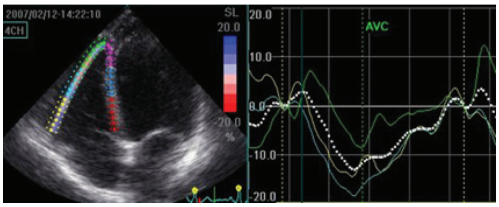

Reduced RV strain in a patient

P223. Global and regional myocardial function is depressed during therapeutic hypothermia

V Kerans, H Skulstad, A Espinoza, PS Halvorsen, T Edvardsen, JF Bugge. Oslo University Hospital, Oslo, Norway

Purpose: Moderate hypothermia is widely used as neuroprotective treatment after cardiac arrest. These patients may have reduced myocardial function due to ischemic damage, but hypothermia itself may also influence on myocardial performance. The effects of moderate hypothermia on myocardial function were explored in this experimental animal study.

Methods: Eight anesthetized pigs were studied in an open chest model. A micromanometer-tipped catheter were positioned in the left ventricle (LV) to measure peak LV pressure (LVP) and LV end-systolic pressure (LVEDP) and calculate the pressure time derivative (dP/dt). Cardiac output (CO) was measured by thermodilution technique from a catheter in the pulmonary artery and systemic vascular resistance (SVR) was estimated. Echocardiography was performed to measure global LV function as ejection fraction (LVEF) by the biplane Simpson method. In addition, regional myocardial function was measured in the LV mid segments of septum and lateral wall (SW, LW) by strain Doppler echocardiography. Negative strain expresses regional systolic shortening. Moderate hypothermia was performed by intravascular cooling. In order to obtain equal conditions during all measurements, right atrial pacing were performed at a fixed frequency of 100 beats per minute for five minutes during normothermia (38°C) and hypothermia (33°C) prior to hemodynamic measurements and echocardiography . Values are given as mean±SD.

Results: Hypothermia reduced spontaneous heart rate in all pigs (87±11 to 75±14 min-1, $p<0.05$). At a paced frequency of 100 beats/min CO decreased from 5.0±0.7 to 3.7±0.6 l/min ($p<0.05$). LVP were reduced from 86±5 to 64±7 mmHg ($p<0.05$) and dP/dt from 1500±504 to 1034±387 ($p<0.05$). LVEF decreased from 58±6 to 51±4% ($p<0.05$). Regional myocardial function was reduced in both the septal and lateral wall, as strain changed from -30.9±7.1 to 17.4±5.0% ($p<0.05$) and from −29.6±8.7 to −18.4±4.5% ($p<0.05$), respectively. Preload measured as LVEDP and afterload assessed as SVR remained unchanged from normothermia to hypothermia (9±3 vs 8±3 mmHg and 882±144 vs 904± 123 dyn·s·cm-5 (n.s.)).

Conclusion: Moderate hypothermia caused reduced global and regional LV function. As loading parameters were unchanged and dP/dt was reduced, hypothermia seems to have a direct negative effect on myocardial contractility. These findings should be taken into considerations when LV function is assessed in patients with therapeutic hypothermia following cardiac arrest.

P437. Plane wave imaging for high frame rate flow visualisation in neonates with congenital heart disease

SA Nyrnes[1], L Lovstakken[2], H Torp[2]. [1]St.Olavs University Hospital, Trondheim, Norway; [2]Norwegian University of Science and Technology, Trondheim, Norway

Purpose: Both technical and patient specific factors are common contributors to diagnostic errors in paediatric echocardiography. The trade-off between frame rate and image quality in Colour Doppler Imaging may be such a technical factor, for instance in neonates due to their high heart rates. In addition, weight below five kilos has been shown to be a patient specific risk factor for diagnostic errors. Thus, with the aim to improve echocardiography imaging in this group, we performed investigations using plane wave imaging.

Methods: Parallel receive beam forming is a technique to receive multiple image lines for each emitted ultrasound pulse. This method has been used to increase the frame rate in Colour Doppler Imaging. However, parallel receive beam forming gives rise to visible image artefacts using conventional focused ultrasound beams. We used linear array transducers (9 MHz and 11 MHz) where plane unfocused beams can be emitted in order to avoid these image artefacts and increase the frame rate, receiving 16 image lines in parallel for every plane transmit pulse.

To visualise flow, we utilized conventional Colour Doppler Imaging and also Blood Flow Imaging, a new flow visualisation technique based on Colour Doppler Imaging and an additional angle independent display of blood speckle movement.

Results: Five neonates (2.2–4.7 kg) with complex congenital heart disease were examined using plane wave imaging. A fivefold increase in frame rate was achieved compared to imaging by the conventional phased array probe in the same pa-

tients. This implied flow images with frame rates up to 100 frames per second.

A sufficient penetration (4–6 cm in depth) was achieved for Colour Doppler Imaging in all cases. Even though the linear probe has a wider footprint than the phased array probe, we managed to obtain optimal standard views. The examples showed that significantly more detailed information of flow could be obtained.

Conclusions: These preliminary data shows that by using plane wave imaging, the frame rate increases substantially while preserving good flow image quality. Hence, the method may improve ultrasound imaging in neonates, but further studies are necessary to confirm if this might reduce diagnostic errors.

P460. Normal values for diastolic pulsed wave tissue Doppler and early mitral inflow

HD Dalen, A Thorstensen, SA Aase, L Vatten, A Stoylen. Norwegian university of science and technology, Trondheim, Norway

Purpose: The aim of the study was to establish normal values for early diastolic mitral annular velocities (e') according to age and sex, and its relation to early mitral inflow (E).

Methods: 1296 persons (20-89 years), 52% women, which participated in the HUNT 3 study were randomly selected to the study. All without known heart diseases, diabetes or hypertension. 30 were excluded after detection of moderate to severe pathology. Participants were stratified according to age and sex. Annular velocities were assessed by pulsed wave tissue Doppler imaging from apical view in the inferoseptal, lateral, inferior and anterior mitral annular sites. E was measured by conventional Doppler with sample volume placed between the mitral leaflet tips.

Results: Mean (SD) E, e' and E/e' are shown in table. Feasibility was ≥98%. All displayed parameters showed a very highly significant difference between sexes and with increasing age (p<0.001). The age dependency of E, e' and E/e' were consistent across sexes and the respective 4 walls (p<0.001). Annular velocities assessed from the different myocardial walls differed significantly, with the highest e' in the lateral annular site and the lowest e' in the inferoseptal site. E/e' also differed significantly when e' was assessed from the inferoseptal and the lateral wall, with corresponding overall E/e' 7.5 and 6.1, respectively (p<0.001).

Conclusions: Normal values for mitral annular early diastolic velocities are presented according to sex and age. Early mitral inflow and early diastolic annular velocities decreased significantly with increasing age, and both measures gave significant higher values in females than in males.

The resulting normal limits for E/e' given by mean ± 2SD are higher than previously reported, which will give upper normal limits in the three age groups of 8.2, 10.4 and 14.3 in women and 8.5, 9.4 and 12.3 in men.

Table 1 Mean (SD) E, e' and E/e'

	E (cm/s)	e' (cm/s)	E/e'	E (cm/s)	e' (cm/s)	E/e'
Age	females			males		
<40	80 (16)	14,6 (2,3)	5.6 (1.3)	75 (15)	14,1 (2,7)	5.5 (1.5)
40-60	74 (15)	11,3 (2,4)	6.8 (1.8)	64 (15)	10,7 (2,3)	6.2 (1.6)
>60	69 (16)	8,2 (3,2)	8.7 (2.8)	61 (14)	8,2 (1,9)	7.7 (2.3)
Mean	75 (16)	11,8 (3,2)	6.7 (2.1)	66 (15)	10,8 (3,0)	6.4 (2.0)

Mean (SD) mitral E (E), early diastolic mitral annular velocity (e') and E/e' ratio according to age and sex.

P459. Normal values for systolic mitral annular velocity assessed by pulsed wave tissue Doppler and color tissue Doppler

HD Dalen, A Thorstensen, SA Aase, L Vatten, A Stoylen. Norwegian university of science and technology, Trondheim, Norway

Purpose: The aim of the study is to establish normal values for systolic mitral annular velocities (S') according to age and sex.

Methods: 1296 persons (age 20-89 years), 52% women, who participated in the HUNT 3 study were randomly selected to echocardiographic examination. Inclusion criteria were freedom from known heart diseases, diabetes or hypertension. 30 were excluded after echocardiographic examination. S' were analyzed in all participants by pulsed wave TDI method (pwTDI) and color TDI method (cTDI) in the inferoseptal, lateral, inferior and anterior mitral annular sites.

Results: Mean (SD) systolic S' (cm/s) is shown in table according to age and sex. Feasibility was ≥98%. There was a highly significant difference between sexes, with increasing age and between the methods (all p<0.001), also significant across the 4 walls (p<0.001). The pwTDI method gave significantly higher velocities than the cTDI method, with mean difference 1.7 (p<0.001).

Annular velocities assessed from the different myocardial walls differed significantly, with the highest velocity in the lateral and inferior annular site and the lowest velocity in the inferoseptal and anterior site (p<0.001).

Conclusions: Normal values for mitral annular systolic velocities are presented according to sex and age. Systolic annular velocities were lower in women than in men, and decreased significantly with increasing age.

Mitral annular velocities warrant a feasible and robust quantification of LV systolic function with both the pwTDI and cTDI methods. The reference values obtained by the two methods differ, and this has to be taken into account when data are used in individual decision making.

Table 1 S' according to a age and sex

	S' (pwTDI)	S' (pwTDI)	S' (cTDI)	S' (cTDI)
Age	females	males	females	males
<40	8,9 (1,1)	9,4 (1,4)	7,6 (1,2)	7,2 (1,0)
40-60	8,1 (1,2)	8,6 (1,3)	6,9 (1,3)	6,5 (1,0)
>60	7,2 (1,2)	8,0 (1,3)	6,4 (1,2)	5,7 (1,1)
Mean	8,2 (1,3)	8,6 (1,4)	6,9 (1,3)	6,6 (1,1)

Values are mean (SD). cTDI=color tissue Doppler imaging, pwTDI=pulsed wave tissue Doppler imaging.

P461. Peak systolic annulus velocity is the best index for measurement of contractility changes.

A Thorstensen, H Dalen, BH Amundsen, A Stoylen. The Norwegian university of science and technology Department of Circulation and Medical Imaging, Trondheim, Norway

Purpose: To compare different echocardiographic methods in detecting contractility changes of the left ventricle.

Methods: 33 healthy volunteers (20–32 years) were examined by echocardiography at rest, during low-dose dobutamine (10 µg/kg/min) (n = 20), and after intravenous administration of beta-blocker (15 mg metoprolol) (n = 20). The following variables were measured: systolic annulus velocity by pulsed-wave (S′(pwTDI)) and colour (S′(cTDI)) tissue Doppler imaging, left ventricular outflow tract peak velocity (LVOT peak), global peak systolic strain rate (SRs) and global end-systolic strain by 2D speckle tracking, systolic mitral annulus excursion by M-mode (MAE(Mm)) and colour tissue Doppler imaging (MAE(cTDI)) and ejection fraction by biplane Simpson (EF). S′ and MAE of the inferoseptal, anterolateral, inferior and anterior walls were averaged.

	Mean (SD) at rest	Mean (SD) during stress	Mean change	Mean (SD) after beta-blocker	Mean change
Heart rate, beats/min	58 (8)	67 (14)	18 %	50 (7)	−14 %
Peak systolic velocity measurements					
S'(pwTDI), cm/s	9.1 (1.0)	15 (1.8)	62 %	7.5 (1.1)	−15 %
S'(cTDI), cm/s	7.6 (0.9)	11.5 (1.0)	52 %	6.5 (0.7)	−13 %
LVOT peak, m/s	1.0 (0.1)	1.7 (0.3)	61 %	0.9 (0.1)	−11 %
Global SRs, s^{-1}	1.2 (0.2)	1.8 (0.3)	49 %	1.0 (0.1)	−10 %
End-systolic measurements					
Global strain	−0.19 (0.02)	−0.23 (0.02)	22 %	−0.19 (0.02)	−3 %
MAE(Mm), mm	16 (2)	20 (2)	31 %	16 (2)	−1 %
MAE(cTDI), mm	15 (2)	18 (2)	23 %	14 (1)	−4 %
EF	0.57 (0.06)	0.70 (0.06)	25 %	0.58 (0.05)	+1 %

Results: The mean (SD) and relative change during stress and beta-blocker are shown in table 1. The relative changes of S′(pwTDI), S′(cTDI), LVOT peak and global SRs were significantly higher (p<0.05 for all) than those of global strain, MAE(Mm), MAE(cTDI), and EF. In addition mean ± 2SD at rest and during stress overlapped for all measures except S′(pwTDI) and S′(cTDI).

Conclusions: Peak systolic velocity measurements were superior to end-systolic measurements in detecting changes in myocardial function. S′(pwTDI) and S′(cTDI) met all criteria for separation between normal function, increased and decreased contractility.

P479. Postsystolic shortening demonstrates viable myocaridum in patients with acute non ST-segment elevation myocardial infarction

C Eek[1], B Grenne[2], H Brunvand[2], S Aakhus[1], K Endresen[1], O Smiseth[1], T Edvardsen[1], H Skulstad[1]. [1]Rikshospitalet University Hospital, Oslo, Norway; [2]Sørlandet Hospital HF, Arendal, Norway

Purpose: Postsystolic shortening (PSS) has been proposed as a marker of viable myocardium in ischemic heart disease. The purpose of this study was to assess the relationship between PSS and

improved regional left ventricular (LV) function after revascularization in patients with acute non ST-segment elevation myocardial infarction (NSTEMI).

Methods: 84 patients with a first acute NSTEMI were examined by speckle tracking echocardiography prior to revascularization (63 by percutaneous coronary intervention and 21 by surgical revascularization), and 9 ± 3 months later. LV function was assessed by peak longitudinal systolic strain in a 16 segments model. Recovery of systolic function from baseline to follow-up was assessed as Δ systolic strain (ΔSS), and negative values represented improvement of function. PSS was defined as the ratio between segmental longitudinal shortening after aortic valve closure divided by total segmental shortening. ΔSS and PSS were both calculated as mean values from the culprit territory, defined as myocardial segments supplied by the infarct related artery.

Results: Systolic function improved from baseline to follow up in the culprit territory, as mean systolic strain values changed from −14.6% to −16.5% (Δ SS -1.9%, p<0.001). A correlation between PSS and Δ SS was found, (r=−0.60, p<0.001). PSS ≥ 0.12 could predict substantial recovery (Δ SS > −5%) with sensitivity 84% and specificity 83%.

Conclusion: Postsystolic shortening is associated with recovery of regional systolic function after revascularization in patients with acute NSTEMI, and can predict substantial recovery with high accuracy in these patients.

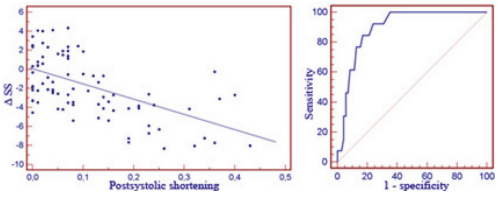

P671. Increased LV counterclockwise rotation in relation to preload reduction in healthy individuals

A Hodt, J Hisdal, M Stugaard, D Atar, E Stranden, K Steine. University of Oslo, Oslo, Norway

Purpose: A reduction in preload, e.g., acute blood loss, increases adrenergic activity which raises left ventricle (LV) inotropy. LV counterclockwise rotation (CCR) has been shown to play an important role in LV ejection mechanics. We sought to investigate the effect of preload reduction on CCR by using lower body negative pressure (LBNP).

Method: Twelve healthy men, 23±2 years of age, were examined at baseline (BL) and at a LBNP of -20 (not shown) and −40 mmHg. Echocardiography was utilized at four different LV short axes levels (basal, papillary-, sub-papillary, apical). 2D ultrasound speckle tracking imaging (STI) was used to measure the rotation at end-systole. Regional end-diastolic and end-systolic areas (EDA; ESA) were measured by tracing the endocardial border. Regional pump-function, i.e., area fraction shortening (FS), was calculated as ((EDA)-(ESA))/(EDA).

Results: See table 1.

Table 1

LV levels	Rotation, degrees		Fractional shortening		EDA %	ESA, %
	BL	-40 mmHg	BL	-40 mmHg		
Basal	-5.2±2.6	-5.3±2.7	0.50±0.06	0.46±0.10	-19.2	-13.9
Papillary	-0.6±3.2	-0.6±4.4	0.52±0.06	0.52±0.08	-18.7	-16.0
Sub-Papillary	3.2±3.6	5.8±4.7[a]	0.57±0.04	0.65±0.08[a]	-19.0	-32,4
Apical	9.3±3.4	12.8±4.7[a]	0.63±0.08	0.75±0.10[a]	-28.3	-51.3

Mean±SD, aP<0.05 vs baseline, % EDA/ESA, percent change between BL and −40 mmHg..

At both the sub-papillary- and apical levels the change in rotation from BL to LBNP −40 mmHg correlated significantly (p<0.05) with the change in ESA and EF. All assessments at LNBP −20 mmHg were in accordance to these measurements.

Conclusions: The increased counter clockwise rotation towards apex at end systole as a response to preload reduction seems to be of mechanistic importance. It may play a key role in the recruitment and forwarding of blood towards the LV outflow tract.

P719. High resolution speckle tracking dobutamine stress echocardiography reveals heterogeneous responses in different myocardial layers. An experimental study on flow distribution and contractile reserve

A Roesner[1], OJ How[1], EJ Aarsaether[1], TA Stenberg[1], TV Kondratiev[2], T Andreasen[2], TS Larsen[2], T Myrmel[2]. [1]Institute of Clinical medicine, University

of Tromsø, Tromsø, Norway; [2]Institute of Physiology, University of Tromsoe, Tromsoe, Norway

Background: Dobutamine-stress- echocardiography can be used to identify viable myocardium. Using speckle-tracking in ultrasound opens for high spatial resolution when assessing these deformation parameters. However, the possibility to place the region of interest (ROI) into different layers of the myocardium creates a potential problem with obtaining standardization in heterogeneously responding layers. We therefore aimed to investigate myocardial strain in four layers at hypoperfusion and with dobutamine challenge.

Methods: In 10 anesthetized open chest pigs the left anterior descending cornonary artery (LAD) was constricted to a constant stenosis with an initial flow-reduction. Fluorescent microspheres were used to measure tissue flow. High-resolution-echocardiography was performed epicardially to calculate strain in 4 myocardial layers in radial, longitudinal and circumferential directions using a speckle-tracking software. Images were obtained at rest, during LAD-constriction and subsequently during hypoperfusion combined with dobutamine stress in both the LAD and the circumflex region (control).

Results: We observed a correlation between flow- and strain reductions in all dimensions of the three inner layers. Dobutamine-stress increased strain differently in the three inner layers, being most predominant subendocardially in the radial direction and mid-myocardially in the longitudinal and circumferential directions.

Conclusion: Flow reductions and dobutamine-stress influence strain-values differently in the various axes and layers of the myocardium. Therefore, standardization and definition of normal and pathological strain responses to dobutamine-stress, will have to take into account detailed specification of strain axes and regions of interest (ROI) including heterogeneous response of the different myocardial layers.

P847. Quantification of mitral regurgitation using HPRF 3D color Doppler

TR Skaug[1], T Hergum[1], T Skjaerpe[2], BH Amundsen[1], H Torp[1], BO Haugen[1]. [1]NTNU, Trondheim, Norway; [2]St.Olavs University Hospital, Trondheim, Norway

Purpose: We have previously described a method for mitral regurgitation quantification using high pulse repetition frequency 3D Doppler, called MULDO. We are exploiting the fact that the power of the Doppler signal is proportional to the amount of blood in the sample volume to find the Vena Contracta Area (VCA). In this paper we have validated the method in vivo.

Method: We isolated the Doppler signal from the mitral jet using MULDO. The Nyquist limit was near the peak jet velocity of the jet. The VCA was found by summing the Doppler power from multiple beams within the vena contracta region and compensating for the attenuation and geometry by a reference beam within the jet.

The regurgitant volume by MULDO (MULDO RV) was calculated as the product of VCA and the velocity time integral of the regurgitant jet as measured by CW Doppler. The regurgitant volume by magnetic resonance imaging (MRI RV) was calculated as the difference between left ventricular and aortic stroke volume. Regurgitant volume was divided into four groups to assess kappa agreement: 1: <30 ml; 2: 30-44 ml; 3: 45-59 ml; 4: >60 ml. Echocardiography was performed to assess mitral regurgitation grade (2D echo MR grade 1-4).

Results: The correlation between MRI RV and MULDO RV (N = 27) was r(s) = 0.82, and the 95% limits of agreement was −3.0 ± 26.2 ml.

The correlation between 2D echo MR grade and MULDO RV was r(s) = 0.66, and kappa agreement was 0.44. Between 2D echo MR grade and MRI RV the correlation was r(s) = 0.82, and kappa agreement was 0.48. The results are shown in the figure.

Conclusion: For moderate to severe regurgitations there was good agreement between MRI RV and MULDO RV. As expected, agreement was lower in mild regurgitations.

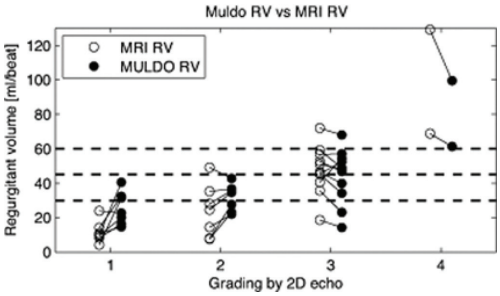

MULDO RV vs MRI RV vs 2D echo MR grade

P1022. Quantitative comparison of LV volumes in 3D echocardiography and cardiac magnetic resonance imaging

G Kiss, B Amundsen, A Thorstensen, H Torp. NTNU, Trondheim, Norway

Objective: To study the different endocardial visualization in three-dimensional echocardiography (3D echo) and cardiac magnetic resonance (CMR) by aligning 3D echo and CMR image slices in three dimensions.

Methods: Six subjects (4 with myocardial infarction) underwent 3D echo and CMR (short- and long-axis cine 2D). In-house developed software was used to align the CMR short- and long-axis slices to compensate for different breath-hold positions. Alignment of the 3D echo and CMR datasets was based on a set of 7 landmarks (apex and six mitral valve attachment points) identified interactively by an experienced cardiologist, both in the 3D echo and CMR data. A least square fitting scheme was employed to achieve optimal 3D alignment.

Results: The average difference (mm) between the drawn contours from 3D echo (red) and CMR (green) was lower in the antero- and inferoseptal segments (Fig. 1, Left: ED contours for both methods overlaid on 4-, 2- chamber 3D echo, Right: bulls eye plot of the average distance between them for all cases). 3D echo underestimated LV volumes and ejection fraction (EF) compared to CMR (end-diastolic (ED) 50 ± 32 ml, end-systolic (ES) 17 ± 39 ml, EF 10 ± 5%). However, the correlations were high: ED r = 0.98, ES r = 0.99, EF r = 0.99.

Conclusions: As expected, 3D echo consistently underestimates LV volumes, and we suggest that this difference is mainly caused by different endocardial visualization in the lateral and inferior walls. This is vital information in studies involving both modalities, and in the development of new automatic 3D echo methods for volume measurements.

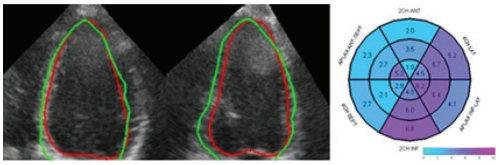

Fig. 1

P1085. Early recovery of function after Acute myocardial infarction evaluated by tissue Doppler strain and strain rate

C Bjork Ingul[1], S Malm[2], E Refsdal[1], B Amundsen[1], A Stoylen[1]. [1]Department of Circulation and Medical Imaging, Medical Faculty, NTNU, Trondheim, Norway; [2]University Hospital of North Norway, Harstad, Norway

Objective: Investigate the changes and time course of recovery of regional myocardial function within the first week, by strain and strain rate tissue Doppler echocardiography following successful primary coronary intervention (PCI) in patients with first time ST-elevation myocardial infarction (STEMI).

Methods: We studied 31 consecutive patients (56 ± 13 years, 25 men) admitted with STEMI with echocardiography for serial assessment, day 1, 2, 3 and 7. All patients underwent coronary angiography and PCI. Mean time to PCI was 15.9 hours (range 5-24 hours). Customized software was used to estimate tissue Doppler based end-systolic strain (S) and peak systolic strain rate (SR) in segments with moderately reduced function (SR < −0.5 s-1 and ≥ −0.75 s-1 and S < 5% and ≥ 10%) or severely (SR ≥ −0.5 s-1, S ≥ −5%) reduced function and according to infarct related artery (IRA).

Results: Mean peak troponin T was 7.0 µg/L, 15 had anterior and 16 inferior infarct. SR and S improved significantly at day 2 both in segments with moderately reduced function (−0.6 ± 0.06 s-1 to −1.0 ± 0.3 s-1 vs. −7.7 ± 1.1% to −14.7 ± 4.1%, p<0.001) and in severely reduced function (−0.2 ± 0.1 s-1 to −1.0 ± 0.5 s-1 vs. 0.5 ± 2 to −11.6 ± 5.5 %, p<0.001), but no further. Wall motion score (WMS) index improved significantly at day 1–2 (1.73 ± 0.2 to 1.64 ± 0.2, p = 0.001) and day 3–7 (1.62 ± 0.2 to 1.56 ± 0.2, p = 0.001). After day 2 there was no difference if the IRA was open or

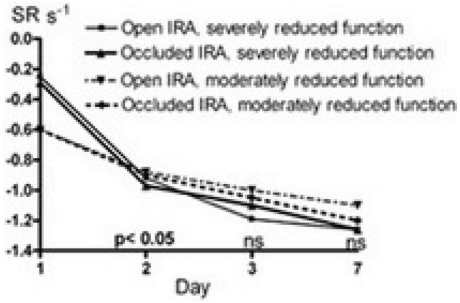

Peak systolic strain rate and IRA

occluded before PCI in the different segments (Figure).

Conclusions: Recovery of regional function after STEMI and PCI occurred within two days and could be detected by both WMS, strain rate and strain, but changes were more evident by strain rate imaging.

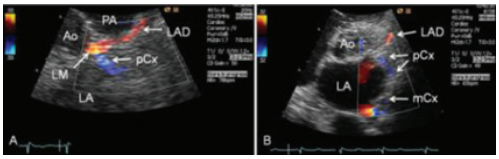

Parasternal view of LM, LAD and Cx

P1098. Feasibility of imaging by transthoracic echocardiography of different segments of all three coronary arteries

E Holte[1], J Vegsundvaag[1], R Wiseth[2], T Hole[1]. [1]Alesund Hospital, Alesund, Norway; [2]St.Olavs University Hospital, Trondheim, Norway

Background: Transthoracic echocardiography (TTE) may be used for direct inspection of various parts of the main coronary arteries for detection of coronary stenoses and occlusions. We aimed to assess the accuracy of TTE to visualise the complete segments of the left main (LM), left descending artery (LAD), circumflex (Cx) and right coronary arteries (RCA).

Methods: 111 patients scheduled for diagnostic coronary angiography because of chest pain or acute coronary syndrome had a TTE study to map the passage of the main coronary arteries. With exception of the LM, the LAD, Cx and RCA were each divided into proximal, middle and distal segments. If any part of the individual segment of a coronary artery with antegrade blood flow was not seen, the segment was labeled as not satisfactorily seen.

Results: Complete visualisation of the various main coronary artery segments was dependant on both the artery and segment investigated, see table.

Conclusion: TTE is a feasible method for complete demonstration of different coronary artery segments with antegrade flow, especially the LM, the proximal segments of LAD and CX, and the middle and distal segments of LAD.

Table 1 Visualisation of LM, LAD, Cx, RCA

Segment	LM n. (%)	pLAD n. (%)	mLAD n. (%)	dLAD n. (%)	pCx n. (%)	mCx n.(%)	dCx n.(%)	pRCA n.(%)	mRCA n.(%)	PDA n.(%)
Antegrade flow (AF)	109(98,2,)	106(95,5)	105(94,6)	101(91,0)	98(88,3)	68(61,3%)	4(3,6%)	44(39,6%)	31(27,9%)	60(54,1%)
Retrograde flow (RF)	0	0	1(0,9)	2(1,8)	0	0	0	0	1(0,9)	5(4,5%)
AF or RF flow	109(98,2,)	106(95,5)	106(95,5)	103(92,8)	98(88,3)	68(61,3%)	4(3,6%)	44(39,6%)	32(27,9%)	65(58,6%)

See text for abbreviations. Additionally, PDA = posterior descending artery, prefixes p = proximal, m = middle, d = distal segments.

❤

En seier beskrevet i detalj kan være vanskelig å skille fra et nederlag.
Jean-Paul Sartre

❤

Menn har bare to ting i hodet. Penger er den andre.
Jeanne Moreau

❤

There is often a large gap between theory and practice... Furthermore, the gap between theory and practice in practice is much larger than the gap between theory and practice in theory.
Jeff Case