FNA ved kul på halsen

- Sensitivitet FNA ved metastase til lymfeknute 83-97%
- Forstørret lymfeknute på hals er vanligste tegn på malignitet i hode og hals
- –Plateepitelkarsinom vanligst (90% >40 år)
- –Nasopharyngeal karsinom, metastase fra spyttkjerteltumor, thyroidea karsinom, melanoma, karsinomer from andre organer
- 75% av branchial cyste er hos pasienter 20-40 år

Benign cyste versus plateepitelkarsinom

Benign Squamous-Lined Cysts	Squamous Cell Carcinoma
Abundant inflammation (PMNs)	Large number of squamous elements
Few squamous epithelial cells	Occasional nuclear hyperchromasia
Bland nuclear features in squamous cells	Occasional nuclear membrane irregularity
Crystals	High N/C ratio

Kvinne 30 år – kul på hals

- Kul på venstre side av hals siste måned

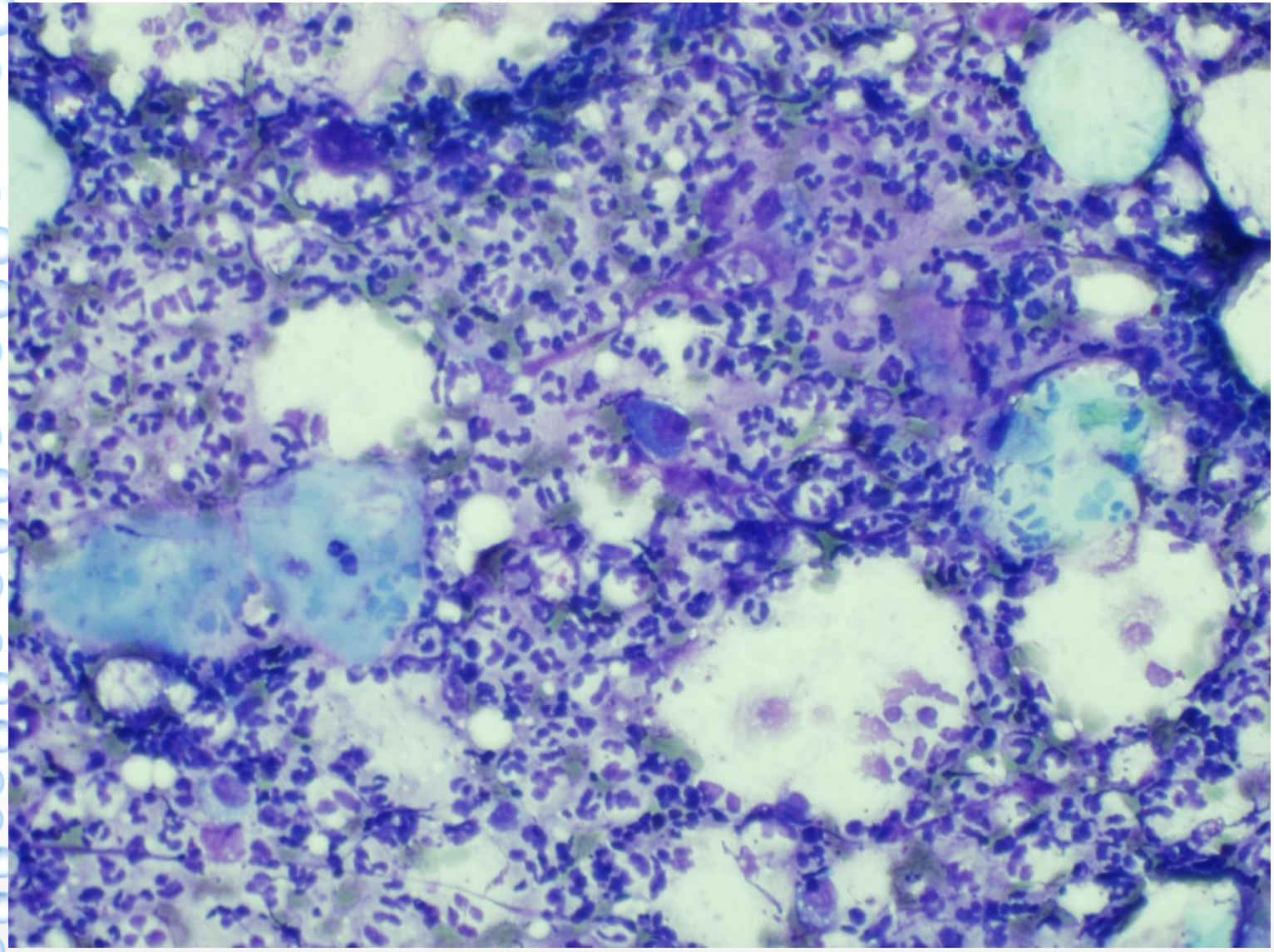

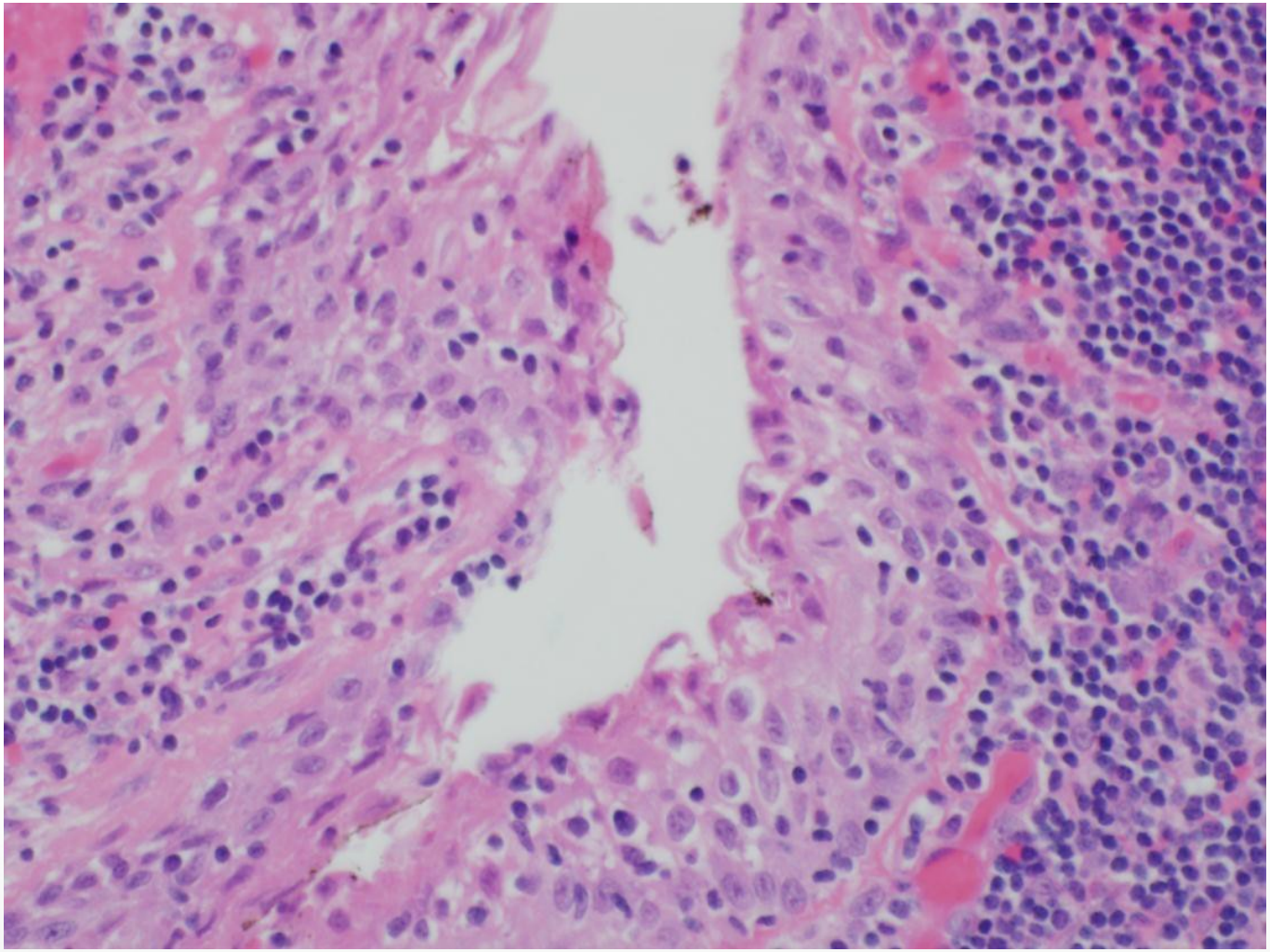

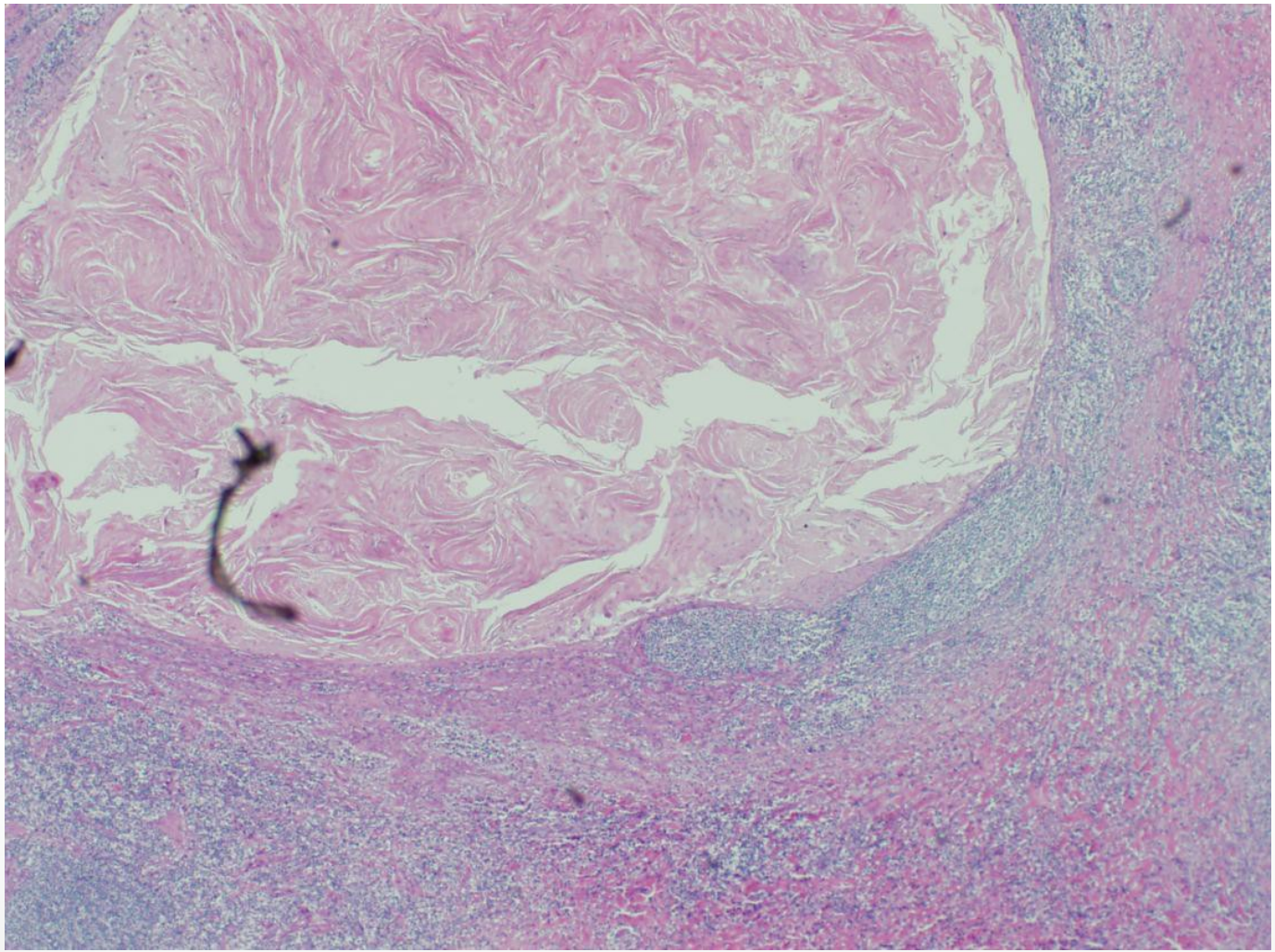

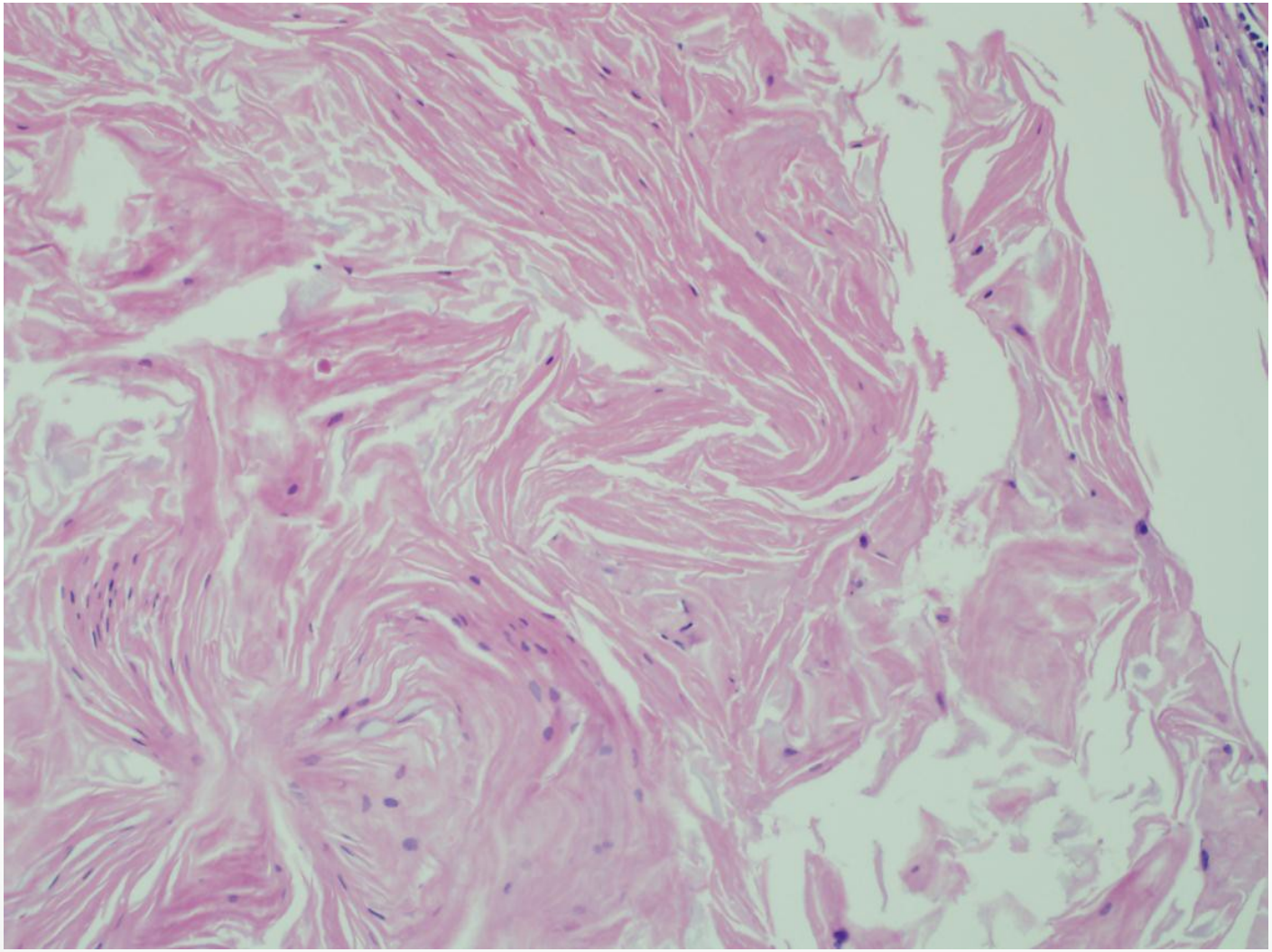

Mann 70 år – kul på hals
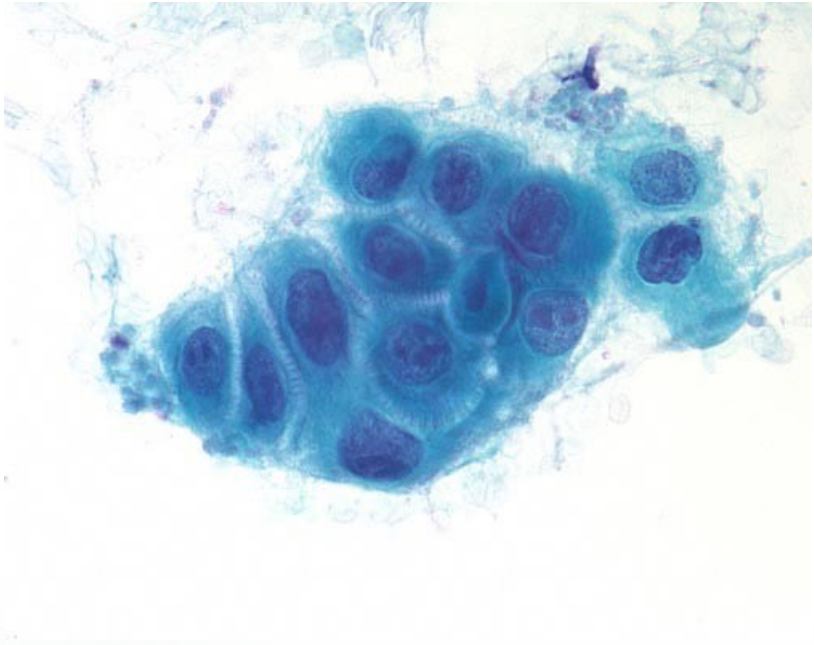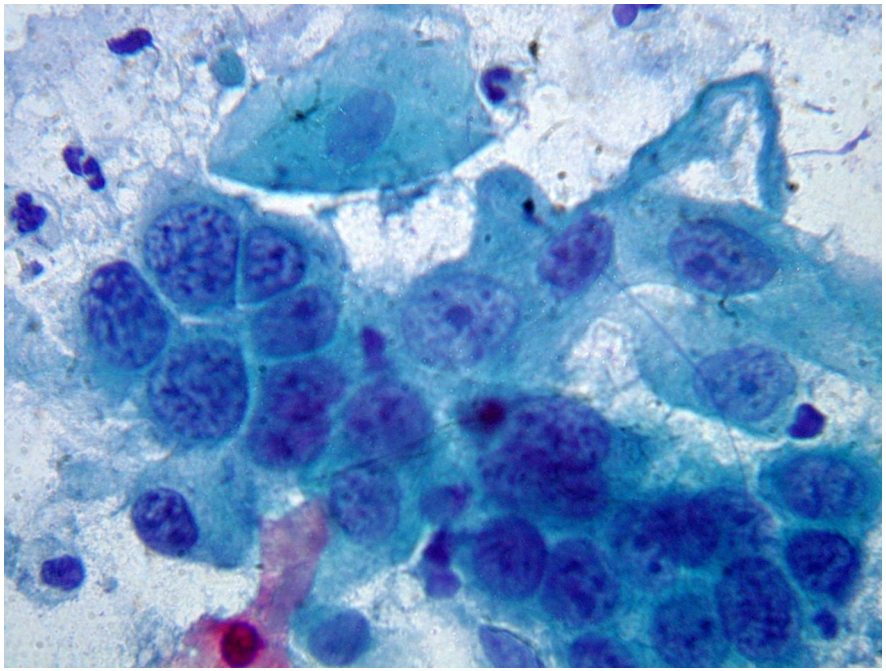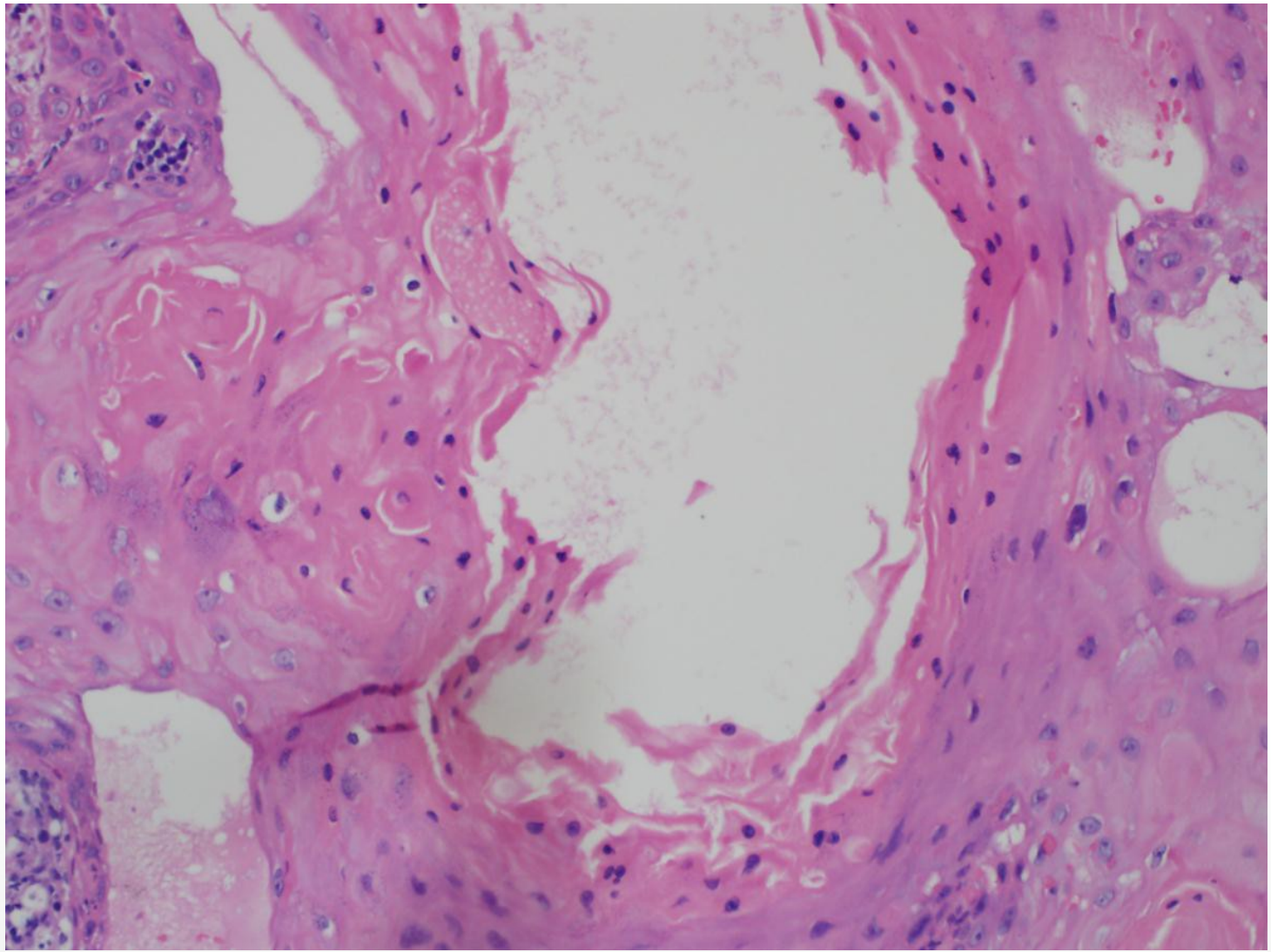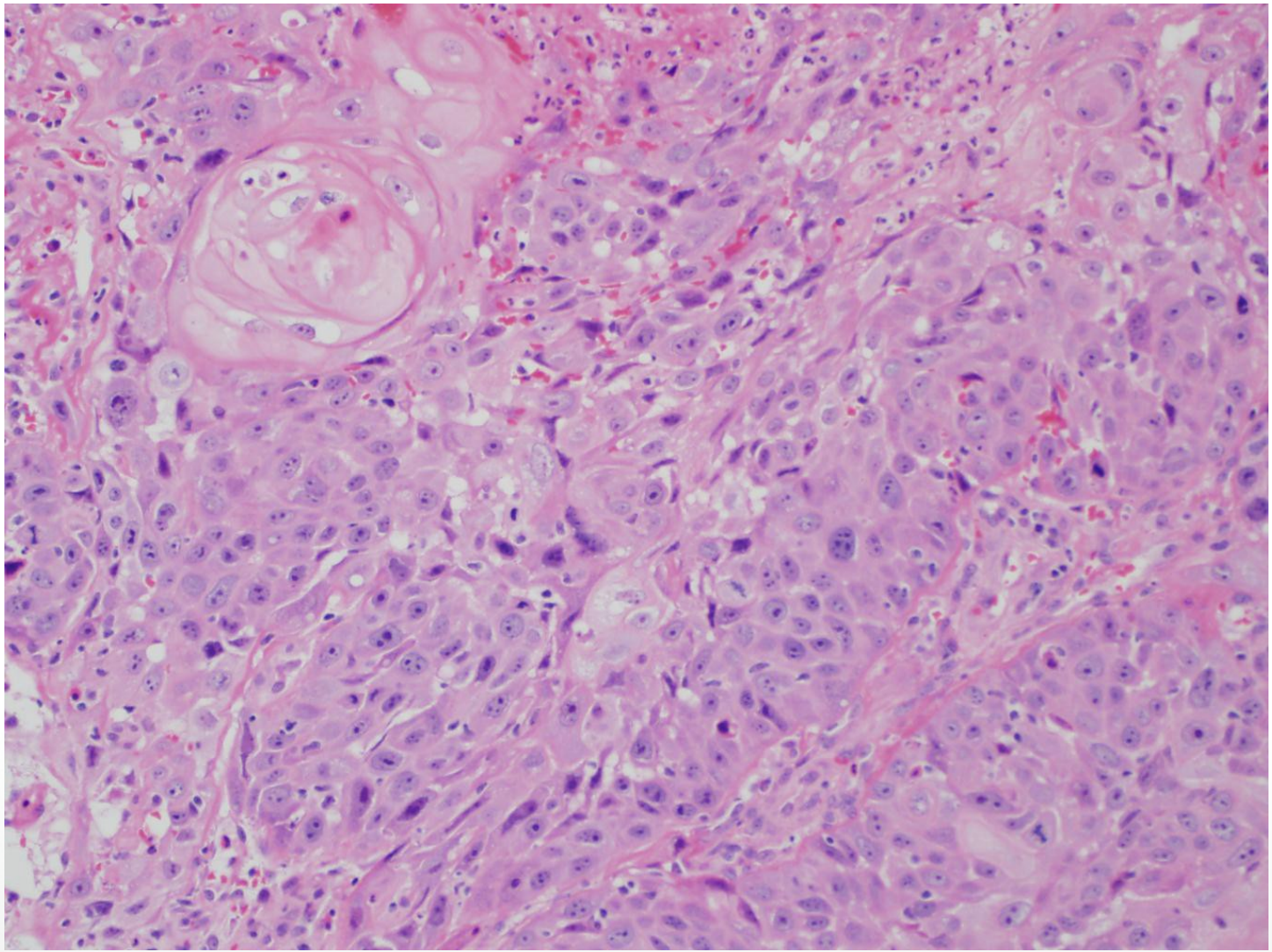
- Kjent kul på høyre side av hals siste to uker